

## Research article

## Transbronchial needle aspiration cytology (TBNA) in submucosal & peribronchial lesions: Sensitive, Superior & complimentary to Conventional diagnostic techniques during bronchoscopy in diagnosing lung cancer

Patil Shital<sup>\*1</sup>, Rajesh Patil<sup>2</sup>, Ayachit Rujuta<sup>3</sup>

1. Associate Professor, Pulmonary Medicine, MIMSR Medical College, Latur, India

2. Associate Professor, Internal Medicine, MIMSR Medical College, Latur, India

3. Professor, Histopathology &amp; Oncopathology, MIMSR medical College, Latur, India

<sup>\*</sup>Corresponding author: Patil Shital, Associate Professor, Pulmonary Medicine, MIMSR Medical College, Latur, India, Email: drsvpatil1980@gmail.com

Received: May 12, 2019; Accepted: June 20, 2019; Published: June 24, 2019

### Abstract

**Background:** Lung Cancer is the leading cause of cancer deaths around the world. Lung cancer accounts for 13.8% of all cancer diagnosis in India. **Materials and Methods:** prospective multicentric observational study conducted during July 2013 to September 2018 at bronchoscopy unit of MIMSR Medical College, and Venkatesh Chest Hospital Latur India to find role of TBNA submucosal & peribronchial lesions in confirming the diagnosis, to document additive yield of TBNA over other techniques like Bronchial Brush (BB), Bronchial wash (BW) and Forcep Biopsy (FB), and to observe any procedure related adverse events especially TBNA in peribronchial lesions. The study included 350 patients on the basis of clinical and radiological features of malignancy. Bronchoscopic lesions were categorized as submucosal lesions (SML) and peribronchial lesions (PBL). TBNA, FB, BB and BW were performed in all the cases during FOB. **Results:** Bronchoscopic abnormalities were documented as SML in 200 cases and PBL in 150 cases. In SML, diagnostic yield of TBNA & FB were 40.05% and 49.50% respectively. Additional diagnostic yield of other CDTs like BB and BW has nil effect on yield difference over forcep biopsy ( $P>0.11$ ). In PBL, diagnostic yield of TBNA, FB & CDTs were 68.66%, 27.33% and 41.33% respectively. Additional CDTs like BB cytology and BW has additive yield to FB from 27.33% to 41.33% in PBL ( $P<0.00001$ ). Sensitivity of TBNA in PBL is 96.19% while that of CDTs is 59 ( $P<0.00001$ ). **Conclusions:** TBNA in submucosal lesions is complimentary to conventional diagnostic techniques in diagnosis of these lesions. TBNA in peribronchial lesions is most sensitive modality over conventional techniques and considered as 'gold standard' in these lesions.

**Keywords:** TBNA, bronchoscopy, submucosal lesions, peribronchial lesions

### Introduction

Lung Cancer is the leading cause of cancer deaths around the world. Globally, Lung cancer is the largest contributor to new cancer diagnosis (1,350,000 new cases and 12.4% of total new cancer cases) and to death from cancer (1,180,000 deaths and 17.6% of total cancer deaths) [1]. The World Health Organization (WHO) estimates that Lung cancer deaths worldwide will continue to rise, largely as a result of an increase in global tobacco use, especially in Asia. Tobacco use is the principal risk factor for Lung cancer, and large proportions of all pulmonary carcinomas are attributable to effects of cigarette smoking [1].

In 1968, Machita and Olympus both introduced commercially available fiberoptic bronchoscopes. Since its introduction; fiberoptic bronchoscope has become an increasingly important diagnostic and therapeutic tool in respiratory diseases including lung cancer [3]. First time, TBNA done through rigid scope by

Schieppati, thereafter Wang developed the flexible type [4]. Various diagnostic techniques like endobronchial biopsy, bronchial washing and bronchial brushing, endobronchial and transbronchial needle aspiration cytology (EBNA & TBNA) are employed during fiberoptic bronchoscopy. Studies have confirmed that employing various techniques in combinations increases the diagnostic yield of fiberoptic bronchoscopy [5].

Transbronchial needle aspiration (TBNA) via flexible bronchoscopy is a well-established sampling tool for diagnosis of lung malignancies [6]. TBNA is superior to all other sampling modalities in peribronchial and submucosal lesions and is on par with bronchoscopic forcep biopsy in endobronchial tumour with an average diagnostic yield of 80 % [6]. On the other hand the previous studies of bronchoscopy in peripheral lesions have shown a great variability in the diagnostic yield,

of 80 % [6]. On the other hand the previous studies of bronchoscopy in peripheral lesions have shown a great variability in the diagnostic yield, with sensitivity for cancer between 20% and 86% [7].

TBNA improves the yield of FOB when added to bronchial washing, brushing and forcep biopsy [8,9]. Despite all these positive aspects, however, TBNA is underutilized [10]. This has been ascribed to lack of formal training, difficulties with needle handling, poor success rate and insufficient cytological laboratory support [8,11]. Although a combination of all these techniques has been shown to increase the diagnostic yield, it is not always possible to perform all these sampling techniques in the same patient [11].

In this study, we observed the role of TBNA in submucosal and peribronchial lesions as compared to other bronchoscopic techniques such as bronchial wash, bronchial brush and forcep biopsy in confirming diagnosis of lung malignancies, with special emphasis on additional yield of TBNA in comparison to other techniques. We also analyzed sole positive yield of TBNA in peribronchial lesions.

### Materials and Methods

This is a prospective multicentric observational study conducted during July 2013 to Sept. 2018 at bronchoscopy unit of MIMSR Medical College Latur India, and Venkatesh Chest Hospital Latur to find the role of TBNA submucosal and peribronchial lesions in confirming the diagnosis of lung Cancer and to find additive yield over other techniques like BB, BW & FB. Total 350 patients with suspected lung malignancy on clinical and radiological basis were included in study after Hospital's Ethical committee approval and written informed consent of patient.

Inclusion criteria:

1. Unexplained paralysis of vocal cord (hoarseness of voice) or stridor,
2. Chest x-ray with radiological features of malignancy. (Coin lesions, Mass lesions, Mediastinal widening, unilateral high hemidiaphragm, Segmental/complete lung collapse, Non-resolving Pneumonia),
3. Normal chest x-ray with high clinical suspicion,
4. Localized monophonic wheeze,
5. Unexplained & recurrent pleural effusion

Exclusion criteria:

1. Coagulopathy which cannot be corrected & Platelets <50,000 per  $\mu$ L,
2. Pulmonary hypertension,
3. Uremia & Serum creatinine >3,
4. Mechanical ventilation with high PEEP,
5. Refractory hypoxemia,
6. Recent myocardial infarction or unstable angina,
7. Significant dysrhythmia and hemodynamic instability,
8. Poor ability to cooperate with procedure.

### The fiberoptic video bronchoscope

FUJINON EPX-201H, fiberoptic video-bronchoscope was used during procedures in all patients enrolled in study by two operators. The upper airway was anaesthetized with 2 ml of

10% lignocaine solution. An additional small quantity of 1% lignocaine is instilled through the bronchoscope for topical bronchial anesthesia, as needed. Patients if he or she was apprehensive were sedated with intravenous midazolam. Bronchoscope was inserted transnasally in about 85% of cases, while in the remaining cases, the transoral route is used. Fluoroscopy facility is also available in our unit.

During bronchoscopy characteristic endoscopic features of Submucosal Lesions are erythema, vascular flares and enhanced rugal pattern, loss of normal bronchial markings, or thickening of mucosa and narrowing of bronchus [12,13]. Peribronchial Lesions during bronchoscopy documented as narrowing of airway due to extrinsic compression of airways by tumour or Lymphadenopathy, or predominant feature of 'bulge' seen in the lumen [12,13].

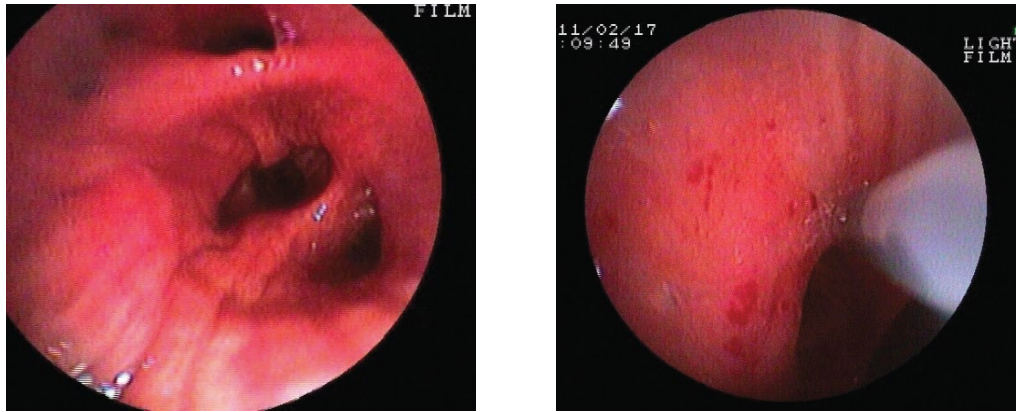
In order to avoid contamination TBNA was performed prior to other procedures such as bronchial brush, forcep biopsy and bronchial wash. TBNA was procedure was done first to avoid false positive and then other techniques were performed. TBNA and forcep biopsy performed in most of the cases and other conventional diagnostic techniques like bronchial wash and bronchial brush decision taken by operator doing bronchoscopy.

TBNA was performed using MW 522 needle catheters (Mill-Rose Laboratories). During bronchoscopy the catheter was passed through the biopsy channel with the needle retracted. Under direct vision the needle was advanced at 45° for submucosal lesions or 90° peribronchial lesions or bulge. In peribronchial lesions needle was inserted in to lesion according to pushing technique introduced by Wang. Once the needle was appropriately placed within the lesion, it was minimally advanced, so that the entire length of the needle will be in the tissue. Then the inner 22-gauge needle was retracted and locked in position. The needle was moved to and fro, under applied suction from a 20-mL syringe. The pressure was released before the needle was taken out from the tissue, to avoid false-positive aspirates. The aspirated material was blown in to four or five slides, smeared, fixed with 95% alcohol and sent for cytological examination at Pathology Department. The statistical analysis was done by using Chi Square test. Significant values of  $\chi^2$  were seen from probability table for different degree of freedom required. P value was considered significant if it was below 0.05 and highly significant in case <0.001.

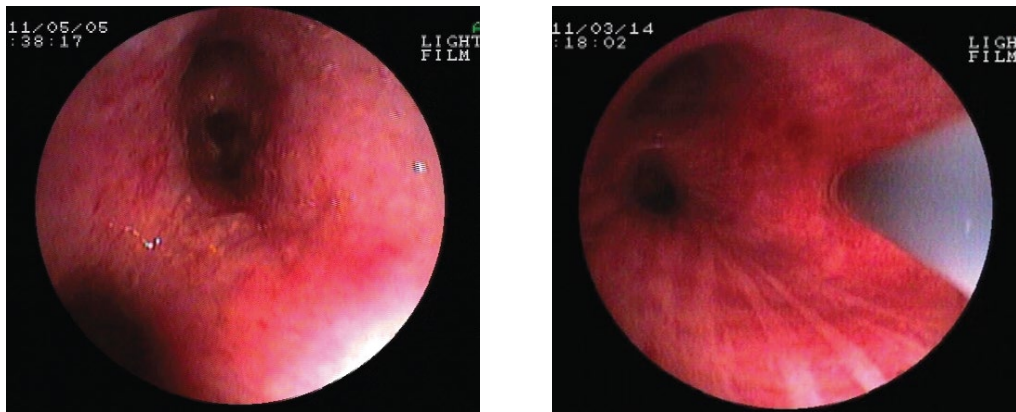
### Observation and Analysis

Total 350 patients, on the basis of clinical and radiological signs of malignancy, between age group 21-87 years with mean age 59.16 years. Males were 81.33% of total, of which 79% were smoker with 57.87% cases were having >40 pack years smoking history. Commoner symptoms were cough (92.33%), Shortness of breath (66.33%) and chest pain (61.33%), while commoner radiological presenting features were hilar mass (51%), parahilar opacity (21%), collapse segmental/lobar (18%).

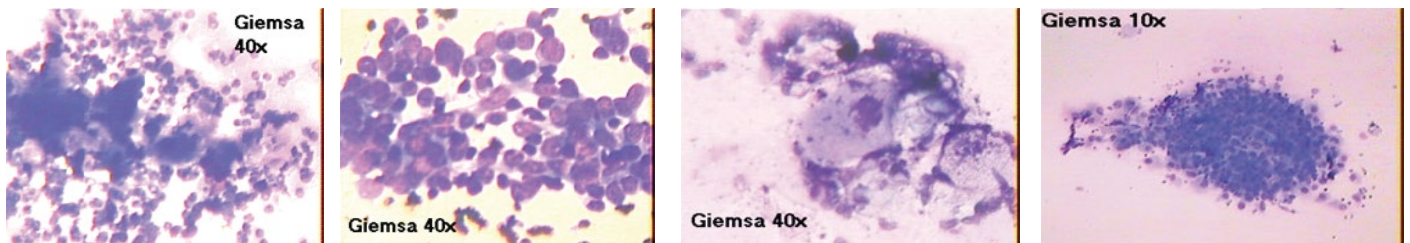
Bronchoscopic abnormalities were documented as Submucosal in 200 cases and Peribronchial in 150 cases. Anatomical location was documented as more on right side of tracheobronchial (62%) as compared to left side of tracheobronchial wall



**Figure 1.** Submucosal lesions with procedures during bronchoscopy (a & b). 1a) Submucosal lesions, 1b) TBNA during submucosal lesions



**Figure 2.** Peribronchial lesions with procedures during bronchoscopy. 2a) peribronchial lesions, 2b) TBNA during peribronchial lesions



**Figure 3.** TBNA Cytology images- Non small cell carcinoma TBNA, Small cell carcinoma TBNA, Squamous cell carcinoma TBNA, Dysplasia TBNA

(38%). Upper lobe bronchi were commoner site on both the sides as compared to other segmental bronchi.

In submucosal lesions, TBNA has low diagnostic yield i.e. 40.05% as compared to forcep biopsy i.e. 49.50%. Additional diagnostic yield of other CDTs like BB and BW has nil effect on yield difference over forcep biopsy ( $P > 0.11$ ) (Table 1).

**Table 1.** Yield of TBNA, Forcep Biopsy in Submucosal Lesions

Results	TBNA	Forcep Biopsy	TBNA plus CDT
Positive	81 (40.05%)	99 (49.50%)	99 (49.50%)
Negative	119	101	101
Total	200	200	200

( $\chi^2 = 4.34$ ,  $df = 2$ ,  $p > 0.11$ )

In peribronchial lesions, TBNA has significant diagnostic yield i.e 68.66% individually as compared to forcep biopsy 27.33% and CDT 41.33%. Additional CDTs like bronchial

brush cytology and bronchial wash has additive yield to forcep biopsy from 27.33% to 41.33% in peribronchial lesions ( $P < 0.00001$ ) (Table 2).

**Table 2.** Yield of TBNA, Forcep Biopsy and CDTs in Peribronchial lesions.

Results	TBNA	Forcep Biopsy	TBNA plus CDT
Positive	101 (68.66%)	41 (27.33%)	62 (41.33%)
Negative	49	109	88
Total	150	150	150

( $\chi^2 = 53.11$ ,  $df = 2$ ,  $p < 0.00001$ )

Sensitivity of TBNA in diagnosing Peribronchial lung malignancy is 96.19% while that of CDTs 59.04%. TBNA has very high sensitivity as compared to CDTs, and is statistically significant in Peribronchial lesions ( $P < 0.00001$ ) (Table 3).



**Table 3.** Sensitivity of TBNA and CDTs (Conventional Diagnostic Techniques) in Peribronchial lesions during bronchoscopy.

Procedure	Positive yield	No yield	Total Diagnosed cases
TBNA	101	4	105
CDT	62	43	105

( $\chi^2=41.69$ ,  $df=1$ ,  $p<0.00001$ )

In submucosal- peribronchial lesions, Cytology (TBNA+B-W+BB) established diagnosis in 200 of 350 diagnosed cases i.e. 57.14%. Histopathology established diagnosis in 140 of 350 diagnosed cases i.e. 40.00%. Cytological investigations are superior to histopathology in submucosal-peribronchial lesions ( $P<0.00001$ ) (Table 4). In Submucosal lesions, forcep biopsy has significant yield (19 cases of 99 diagnosed cases) solely as compared to TBNA (6 cases of diagnosed 99 cases). In peribronchial lesions, TBNA has significant yield (31 cases of 101 diagnosed cases) solely as compared to forcep biopsy (10 cases of 101 cases) ( $p<0.0001$ ) (Table 5).

**Table 4.** Statistical analysis of Cytology and Histopathology yield in Submucosal-Peribronchial Lesions.

Results	TBNA+B-W+BB (Cytology)	Histopathology (Forcep Biopsy)
Positive	200 (98.03%)	140 (68.62%)
Negative	150	210
Total	350	350

( $\chi^2 =20.58$ ,  $df=2$ ,  $p<0.00001$ )

**Table 5.** Sole positive yield of TBNA and Forcep biopsy in Submucosal and Peribronchial lesions.

Procedure	Submucosal Lesions (n=99 cases)	Peribronchial Lesions (n=101 cases)
TBNA	6	31
Forcep Biopsy	19	10

( $\chi^2 =16.79$ ,  $df=1$ ,  $p<0.0001$ )

## Discussion

Yield of TBNA, forcep biopsy and other conventional diagnostic techniques in submucosal lesions

Out of 200 cases with submucosal abnormalities 99 cases were diagnosed by combination of all bronchoscopic procedures including TBNA, forcep biopsy, bronchial brush cytology and bronchial wash. Total yield of all fiberoptic bronchoscopy guided procedures in submucosal lesions is 49.50%. Roth et al. [14] reported diagnostic yield in submucosal lesions 34.4% in their study.

TBNA has low yield i.e. 40.05% as compared to forcep biopsy i.e. 49.50% in diagnosis in submucosal lesions. Additional diagnostic yield of other CDTs like BB and BW has nil effect on yield difference over forcep biopsy ( $P>0.11$ ). Karahalli E et al. [15] and Lundgren et al. [16] reported that TBNA had lower diagnostic yield than forcep biopsy in submucosal lesions. Roth et al. [14] concluded no additional yield of bronchial brush and small volume lavage over TBNA and forcep biopsy in submucosal lesions. Though yield of TBNA is low, it has 81.81% sensitivity in diagnosing disease in submucosal lesions in our study. Khoe et al. [17] reported 83% sensitivity of TBNA in their study.

In our study, it is observed that TBNA plus CDTs has no added advantage over CDTs alone and Forcep Biopsy has individually comparable yield with all CDTs like BB and BW. Caglayan et al. [12] reported TBNA combined with CDTs has no additional yield over CDT in submucosal lesions. Yield of TBNA, Forcep biopsy and other conventional diagnostic techniques in Peribronchial Lesions (bulge)

In peribronchial lesions, TBNA has significant diagnostic yield i.e 68.66% individually as compared to forcep biopsy 27.33% and CDT 41.33%. Additional CDTs like bronchial brush cytology and bronchial wash has additive yield to forcep biopsy from 27.33% to 41.33% in peribronchial lesions ( $P<0.00001$ ). Ladina Joos et al (18) reported yield of TBNA was 43.6% in their study. Harrow EM et al. [19] reported success rate of TBNA up to 80% for peribronchial disease. Additional CDTs like bronchial brush cytology and bronchial wash has additive yield to forcep biopsy from 27.33% to 41.33% in peribronchial Lesions ( $P<0.0001$ ). Dasgupta et al. [6], Govert et al. [20] found combination of higher yield of TBNA over CDT and have increased yield CDT over forcep biopsy alone in their studies. Caglayan et al. [12] in peribronchial disease reported diagnostic rate was 52% by CDT, 87% by TBNA plus CDT and superiority of combination over CDT was significant ( $p<0.001$ ).

TBNA was the only diagnostic technique in 31 out of 101 cases of peribronchial lesions in our study. Sole yield of TBNA in our study is 30.69% (31/101) which is significantly higher than any Individual CDTs. Caglayan et al. [12] reported 34.3% yield of TBNA as a sole in their study in peribronchial lesions.

In our study Sensitivity of TBNA in diagnosing lung malignancy is 96.19% while that of CDTs 59.04%.TBNA has very high sensitivity as compared to CDTs, and is statistically significant in Peribronchial Lesions. ( $P<0.01$ ) Khoo et al. [17] reported sensitivity of TBNA 89% and Shure and Fedullo et al. [13] reported sensitivity of CDTs 71% in their study.

## Yield of TBNA, Forcep biopsy and other conventional diagnostic techniques in Submucosal and peribronchial Lesions (combined analysis)

Unlike exophytic endobronchial mass lesion, the diagnostic yield of CDT is low in submucosal and peribronchial diseases, where the mucosa was generally intact. TBNA enables penetration into the submucosa and access to the tumor through the bronchus wall in peribronchial disease, and usually diagnosis is available solely by TBNA [6,12,14,15,18,21-24]. Average Yield of all Fiberoptic Bronchoscopy guided procedures in Submucosal-Peribronchial Lesions in our study is 200 cases out of 350 cases i.e. 57.14%. Roth et al. reported 54.2% yield in submucosal-peribronchial group in their study. Gellart AR et al. reported yield of 55% in their study [25].

Sensitivity of forcep biopsy in diagnosing lung malignancy in submucosal-peribronchial lesions is 63.63% i.e. (140/200) and that of TBNA is 91.00% (182/210) in diagnosing lung malignancy in submucosal-peribronchial lesions. TBNA is Valuable technique and significant difference between the yield when compared with forcep biopsy ( $P<0.001$ ). Kaçar N et al. [21] reported 69.04% and 94.40% sensitivity of forcep biopsy and TBNA respectively in submucosal-peribronchial lesions

which was highly significant as observed in our study ( $P < 0.008$ ). Caglayan et al. [12] reported sensitivity of TBNA 87% and of forcep biopsy 52% which is also highly significant ( $p < 0.001$ ).

#### Other important observations during study

#### Results of TBNA in Submucosal lesions, fairly comparable with Forcep biopsy; still overall diagnostic yield is not up to mark?

In present study we documented, total yield of all fiberoptic bronchoscopy guided procedures in submucosal lesions is 49.50%. TBNA has low yield i.e. 40.05% as compared to forcep biopsy i.e. 49.50% in diagnosis in submucosal lesions. Additional diagnostic yield of other CDTs like BB and BW has nil effect on yield difference over forcep biopsy ( $P > 0.11$ ).

Possible explanation for mentioned fact as per our observation in this study is that, submucosal lesions have various bronchoscopic abnormalities like erythema, vascular flares and enhanced rugal pattern, loss of normal bronchial markings, or thickening of mucosa and narrowing of bronchus which can be equally documented in infectious, inflammatory and malignant process. Negative yield was confirmed by all possible diagnostic modalities as pathology documented in these type of lesions may be because of true infective, inflammatory process rather than malignant pathology.

#### Without TBNA during routine bronchoscopy in Peribronchial lesions overall yield is decreased, & need for repeat procedures are increased

When TBNA cytology was showing malignant cells with no histological type and forcep biopsy report was inconclusive or non-diagnostic. In such cases we performed repeat bronchoscopy procedure for further additional samplings. Repeat bronchoscopy can be prevented by ROSE (rapid on site evaluation) technique, which aids immediate diagnosis and helps in guiding adequacy of samples during bronchoscopy. We have rapid on site evaluation cytology facility which was helped us in decreasing repeat procedure. We require average 9 passes of TBNA in these difficult cases, and routinely we preferred 6 TBNA passes to get adequate yield and final confirmatory diagnosis. Diacon A et al. [26] reported ROSE detected diagnostic material at first site sampled in 50% of all procedures, 64% of bronchoscopy procedures were terminated early because of early diagnosis and in 35% cases only sampling methods other than TBNA is required.

#### TBNA procedure related adverse events documented in present study

Thirteen patients in our study was developed hypoxemia during procedures and was corrected by oxygen supplementation and finally we completed the procedure with supplementation of oxygen. We usually provide oxygen supplementation as a protocol whenever oxygen saturation falls below 90% and terminate the procedure if it is not correctable with oxygen supplementation. Bollinger CT et al. [4] documented hypoxemia during bronchoscopy procedure and recommended monitoring oxygen saturation with pulse oximetry during procedure.

Other complications like minor bleeding and significant

bleeding was documented in 26 & 9 cases respectively of total 350 in our study, and manifested as post bronchoscopy hemoptysis. We were used instillation of cold saline and topical adrenaline bronchoscopically to manage bleeding. Pneumothorax which is a minor and rare complication of TBNA is observed in 0.014% (5/350) cases. Mortality rate in our study during bronchoscopic procedures was zero percent. Bollinger CT et al. [4], Jin F et al. [27] ACCP Guidelines on Interventional Pulmonology 2003 [28] reported mortality rate of 0.01% and complication rate 0.7% in their study. Other potentially life threatening complications like respiratory depression, airway obstruction, arrhythmias and infections were also not observed in our study.

#### Conclusion

Conventional TBNA is underutilized & less utilized routinely during bronchoscopy. Bronchoscopic characterization of lesions as endobronchial, submucosal and peribronchial is more useful tool to guide use of TBNA. TBNA in submucosal lesions is complimentary to conventional diagnostic techniques like forcep biopsy and other cytology techniques like bronchial wash and bronchial brush. TBNA in Peribronchial lesions is most sensitive modality over conventional techniques and considered as 'gold standard' in these lesions.

TBNA is cost effective and it will decrease need for repeat bronchoscopy. TBNA should be considered routinely during bronchoscopy where EBUS TBNA is not available or not affordable in setting like India. More emphasis should be given to TBNA training especially in interventional pulmonology centers.

#### Compliance with Ethical Standards

1. Funding-nil (no funding or any grant utilized)
2. Disclosure of potential conflicts of interest- "we declare that we have no conflicts of interest."
3. Research involving human participants and/or animals- All procedures performed in studies involving human participants were in accordance with the ethical standards of the institutional and/or national research committee and with the 1964 Helsinki declaration and its later amendments or comparable ethical standards.
4. Informed consent- Informed consent was obtained from all individual participants included in the study.

#### References

1. Siegel R, Ward E, Brawley O, et al. cancer statistics, 2011: the impact eliminating socioeconomic and racial disparities on premature cancer deaths. *CA Cancer J clin.* 2011; 61(4):212-36.
2. Parkin DM, Pisani P, Lopez AD, et al. At least one in seven cases of cancer is caused by smoking. Global estimates for 1985. *Int J Cancer.* 1994; 59(4):494-504
3. Miyazawa T. History of the flexible bronchoscope. In: Bolliger CT, Mathur PN, eds. *Interventional bronchoscopy.* Basel: Karger. 2000; 16-21
4. CT. Bollinger, D Plekker, CFN Koegelenberg. Different Techniques in Bronchoscopy *Eur Respir Mon.* 2010. 45, 1-17.
5. Choudhry MK, Rasul S, Iqbal ZH, et al. Fiberoptic bronchoscopy-Role in the diagnosis of bronchogenic carcinoma. *Biomedica.* 1999; 14:32-6.
6. Dasgupta A, Minai OA, Mehta AC. Transbronchial needle aspiration of central and peripheral lesions; in Bollinger CT, Mathur PN (eds): *Interventional bronchoscopy.* Basel Karger. 2000; 66-70

7. Gasparini S, Ferretti M, Secchi EB, et al. Integration of transbronchial and percutaneous approach in the diagnosis of peripheral pulmonary nodules or masses. Experience with 1,027 consecutive cases. *Chest*. 2000; 108:131-137.
8. Mazzone P, Jain P, Arroliga AC, et al. Bronchoscopy and Needle aspiration techniques for diagnosis and staging of lung cancer. *Clin Chest Med*. 2002; 23:137-158
9. Bilaceroglu S, Gunel O, Cagirici U, et al. Comparison of endobronchial needle aspiration with forcep and brush biopsies in the diagnosis of endobronchial cancer. *Monaldi Arch Chest Dis*. 1997; 52:13-17
10. Lachman MF, Schofield K, Cellura K. Bronchoscopic diagnosis of malignancy in the lower airway: A cytologic review. *Acta Cytol* 1999; 39:1148 -51
11. Haponick EF, Cappelari JO, Chin R, et al. Education and experience improves transbronchial needle aspiration performance. *Am J Resp Crit Care Med*. 1995; 151:1998-2002
12. Caglayan, Akturk, Ali Fidan, et al. Transbronchial needle aspiration in the diagnosis of endobronchial malignant lesions. *Chest*. 2005;128(2):704-8
13. Shure D, Feddulo PF. Transbronchial Needle Aspiration in Diagnosis of Submucosal and Peribronchial Bronchogenic carcinoma. *Chest* 1985; 88, 49-51.  
Roth K, Hardie JA, Andreassen AH, et al. Predictors of diagnostic yield in bronchoscopy: a retrospective cohort study comparing different combinations of sampling techniques. *BMC Pulm Med*. 2008; 8:2.  
E Karahalli, A Yilmaz, H Türker, et al. Usefulness of various diagnostic techniques during fiberoptic bronchoscopy for Endoscopically visible tumours *Respiration*. 2001; 68 (6):611-4  
Lundgren R, Bligman F, Angstrom T. Comparison of transbronchial fine needle aspiration biopsy, aspiration of bronchial secretion, bronchial washing, brush biopsy and forceps biopsy in the diagnosis of lung cancer. *Eur J Respir Dis*. 1983; 64:378-385
17. Khoo K, Chua GSW, Mukhopadhyay A, et al. Transbronchial needle aspiration: initial experience in routine diagnostic Bronchoscopy. *Respir Med*. 2003; 97:1201-1204
18. Joos L, Patuto N, Chhajed PN, et al. Diagnostic yield of flexible bronchoscopy in current clinical practice: SWISS MED WKLY. 2006 ; 136 : 155 – 159.
19. Harrow EM, Abi-Saleh W, Blum J, et al. The utility of transbronchial needle aspiration in the staging of bronchogenic carcinoma. *Am J Respir Crit Care Med*. 2000; 161: 601-607
20. Govert JA, Dodd LG, Kussin PS, et al. A prospective comparison of fiberoptic transbronchial needle aspiration and bronchial biopsy for bronchoscopically visible lung carcinoma. *Cancer*. 1999; 87(3):129-34
21. Kaçar N, Tuksavul F, Edipoğlu O, et al. Effectiveness of transbronchial needle aspiration in the diagnosis of exophytic endobronchial lesions and submucosal/peribronchial diseases of the lung. *Lung Cancer*. 2005; 50(2):221-6. Epub 2005 Jul 19.
22. Rajamani S, Mehta AC. Transbronchial needle aspiration of central and peripheral nodules. *Monaldi Arch Chest Dis*. 2001; 56:436-445
23. Wang KP. Transbronchial needle aspiration and percutaneous Needle aspiration for staging and diagnosis of lung cancer. *Clinics in Chest Med* .1995; 16:535-552
24. Rawat J, Dua R, Saini S. Clinico-pathological profile of lung cancer in uttarakhand. *Lung India*. 2009; 26(3):74-76.
25. Gellert AR, Rudd RM, Sinha G, et al. Fibreoptic bronchoscopy: effect of experience of operator on diagnostic yield of bronchial biopsy in bronchial carcinoma. *Br J Dis Chest*. 1982; 76: 397-399.
26. Diacon A, Schuurmans M, Bollinger CT. Utility of Rapid on Site Evaluation of Transbronchial Needle Aspirates. *Respiration*. 2005;72:182-188
27. Jin F, Mu D, Chu D, et al. Severe complications of bronchoscopy. *Respiration*. 2008; 76: 429-433.  
Interventional Pulmonary Procedures: Guidelines from the American
28. College of Chest Physicians. Armin Ernst, Gerard A. Silvestri and David Johnstone *Chest*. 2003; 123; 1693-1717

To cite this article: Shital P, Patil R, Rujuta A. “Transbronchial needle aspiration cytology (TBNA) in submucosal & peribronchial lesions: Sensitive, Superior & complimentary to Conventional diagnostic techniques during bronchoscopy in diagnosing lung cancer”. *European Journal of Respiratory Medicine*. 2019; 1:1.

© Shital P, et al. 2019.